


Granulomatous Appendicitis- A Rare Case Report

SUYASH RASTOGI¹, USHA MUNIYAPPA²

ABSTRACT

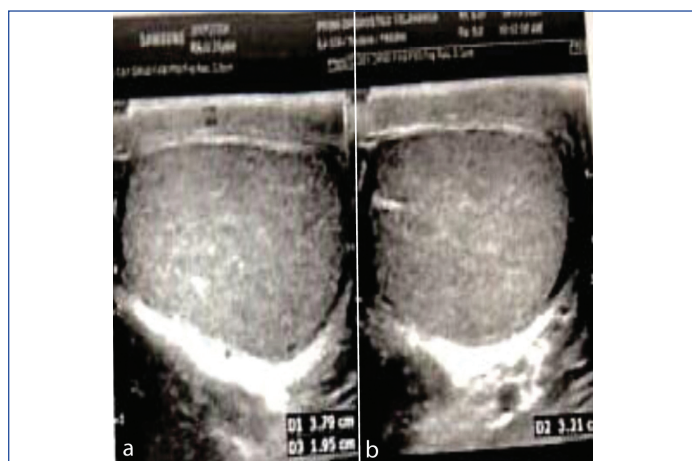In 1953, Meyerding and Bertram were the first individuals to report non-specific granulomatous inflammation in the appendix. Granulomatous appendicitis is a rare condition, accounting for less than 2% of cases. However, idiopathic granulomatous appendicitis is very rare, and diagnosis is usually made by excluding all other conditions. It is challenging to diagnose tuberculous appendicitis based on clinical findings, hence histopathological examination is required. Hereby, authors report a case of 26-year-old male who presented with pain abdomen in the Department of Surgery. On imaging, appendix was thickened, and acute appendicitis was considered as a probable diagnosis. On histopathological examination, it was diagnosed as granulomatous inflammation suggestive of tuberculosis. The present case is presented for its rarity as appendicitis is considered as an abdominal emergency, so prompt management and diagnosis is required by excluding all other causes of granulomatous inflammation in appendix.

Keywords: Appendiceal granulomas, Appendix, Mycobacterium tuberculosis

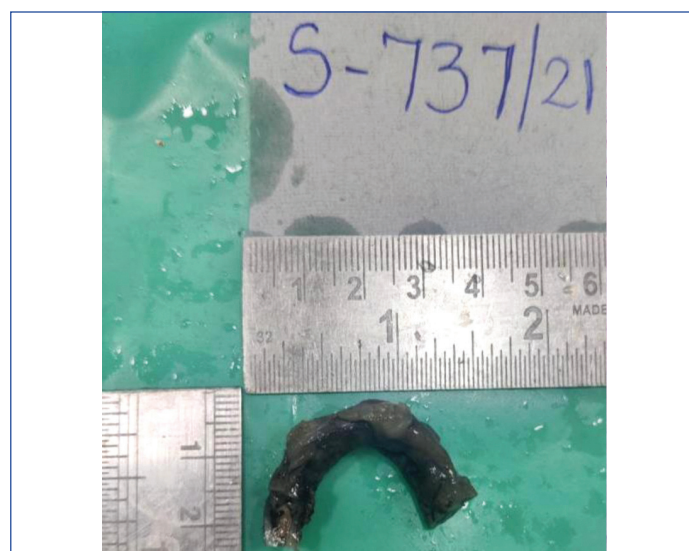CASE REPORT

A 26-year-old male presented to the outpatient department with intermittent pain abdomen and pain in scrotal region for two months. Pain was colicky in nature and associated with vomiting and fever. On examination, patient was febrile and showed marked tenderness in the right iliac fossa with all his vitals within normal limits. On his initial work-up pulse rate was 80 bpm, Blood Pressure (BP) 120/70 mmHg, SpO₂ 99% on room air, however his leukocyte counts and Erythrocyte Sedimentation Rate (ESR) were raised to 14800 cells/cumm and 62 mm/hr, respectively. Computed tomography of abdomen and pelvis showed retrocaecal and thickened appendix with periappendiceal stranding of fat. Since, he was having pain in the scrotal region, high resolution ultrasound and doppler of scrotum was done which showed no significant abnormality [Table/Fig-1]. Radiating pain to scrotum has many differential diagnoses in adult patients such as testicular torsion and infections (epididymitis, epididymo-orchitis). With history, physical examination and ultrasound, testicular torsion and infections were ruled out, since the pain was colicky in nature. Inflammatory bowel disease also was not considered as provisional clinical diagnosis, hence the probable diagnosis of acute appendicitis was made. Radiating pain to scrotum in case of acute appendicitis is a diagnostic feature. Patient was taken for surgery and underwent interval laproscopic appendicectomy under general anaesthesia. Consent was taken before surgery. In intraoperative period,

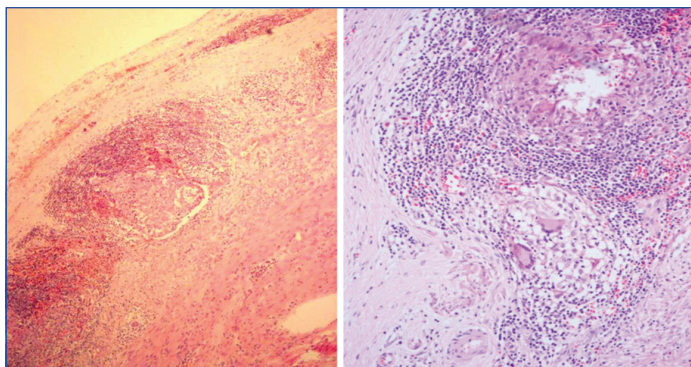
retrocaecal appendix was seen with adhesions. Postoperative period was uneventful. The authors received appendicectomy specimen in 10% buffered formalin with periappendiceal fat measuring 4 cm in length. On external surface, serosa appeared dull and congested [Table/Fig-2]. On cut surface, lumen was identified and mucosa appeared hyperemic. Few fecaliths were also seen. Tissue sections were processed and the slides were stained with Haematoxylin and Eosin (H&E). Histopathological examination of the appendix showed ulcerated appendiceal mucosa with hyperplastic lymphoid follicles in lamina propria. Multiple transmural granulomas with caseous necrosis were seen composed of epithelioid cells, langhans and foreign body giant cells surrounded by cuff of lymphocytes [Table/Fig-3-5]. Based on histopathological findings, inflammatory bowel disease and Tuberculosis (TB) appendicitis was considered as differential diagnosis, however cryptitis, crypt abscess and basal plasmacytosis was not seen in the sections studied. Patient was examined for primary source of TB and advised for colonoscopy to rule out Crohn's disease, however colonoscopy was unremarkable. Three consecutive early morning sputum samples were taken, which came out negative for acid fast bacilli. There was no family history of TB. Patient was started on standard anti-TB drugs, course similar to pulmonary TB.



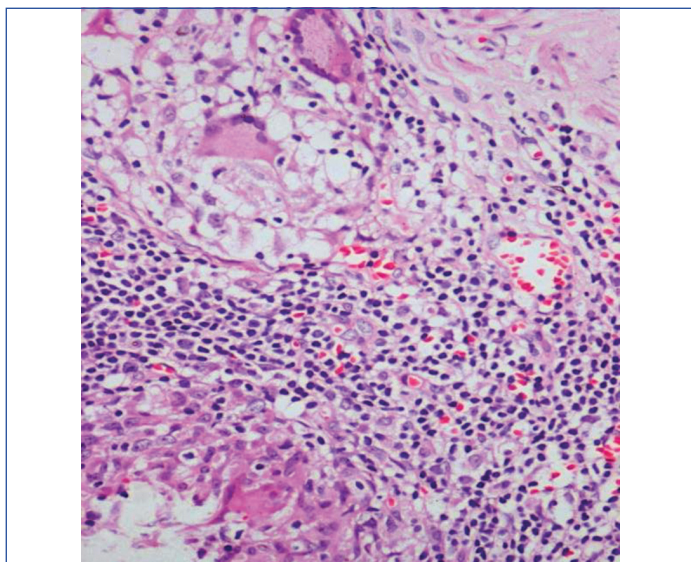
[Table/Fig-1]: High resolution ultrasound of scrotum showing normal echogenicity without any abnormality.



[Table/Fig-2]: Gross picture showing dull and congested serosa.



[Table/Fig-3]: Photomicrograph showing well-formed granuloma (H&E 40X).
[Table/Fig-4]: Photomicrograph showing granuloma surrounded by cuff of lymphocytes (H&E 100X). (Images from left to right)



[Table/Fig-5]: Photomicrograph showing Langhans type giant cells suggestive of TB (H&E stain, 400X).

DISCUSSION

Granulomatous appendicitis is a very rare entity and poorly understood with range of occurrence of appendiceal granulomas from 0.1% to 2%. Granulomatous inflammation is a morphological pattern of chronic inflammation where immune system attempts to isolate foreign substances that it is otherwise not able to eliminate [1,2]. Epithelioid granulomas are usually associated with systemic granulomatous conditions and certain infections. These granulomas are known to occur in gastrointestinal tract. In under-developed countries, there is higher incidence of these granulomas which is often associated with TB [3]. In extrapulmonary TB, appendicular TB has been considered as a rare form of TB, and it is usually seen secondary to infections elsewhere in the abdomen. Appendix is involved in about 1% of the case, however ileocaecum area is involved in over 40% of cases of abdominal TB [4,5]. Tubercular appendicitis is a rare manifestation, with occasional case reports in literature. It was first recognised by Corbin in 1873 [6,7].

TB is a major public health problem in developing countries like India. India accounts for one-fifth of the global TB incident cases [8]. Even though appendix is situated close to ileocaecal region, its involvement is rare. Primary TB of the appendix presenting as appendicular abscess is even rarer with incidence of 0.1-0.6% [9]. In recent studies, Shah RC et al., reported 10 cases of tubercular appendicitis over a period of 10 years [10]. In a study done by Gupta AK et al., on 2921 appendectomies specimens, only 2.3% (67) of cases were tubercular appendicitis [11]. Some authors, including Scott and James, suggest that in their experience appendicular TB is practically always associated with the same infection in the caecum, whereas most observers are familiar with ileocecal or intestinal TB being frequently found with no involvement

of the appendix suggesting that the latter is usually secondarily affected [4].

Mittal VK et al., reported that tuberculous infection of the appendix might result not only from contiguity to a neighboring lesion due to the minimal contact of the luminal mucosa of the appendix with the intestinal contents but also by either the obvious hematogenous route from a distant focus, such as a pulmonary or bronchial lymph node, or by the infected contents of the intestinal tract [12].

Most of the cases of granulomatous appendicitis are idiopathic and remained unexplained; however, there are several causes which can be accounted for granulomatous inflammation in appendix. Recent studies suggested that majority of idiopathic appendiceal granulomas happens due to either infection with *Yersinia* (25%) or as a result of interval appendectomy (55%). In our case, interval appendectomy was performed which could have resulted in granulomatous inflammation of appendix. The other conditions which lead to this condition were explained by unusual causes, for example, foreign body, sarcoidosis, and infection (10%). However, only 5-10% were related to Crohn's disease. These findings suggest that truly idiopathic appendiceal granulomas are indeed extremely rare [1,14].

Symptoms of the disease are commonly non specific, hence presumptive diagnosis is really difficult to make. In our case report, patient was not having preoperative diagnosis of TB. Radiologic and laboratory findings of appendicular TB are often non specific, whereas histopathological examination shows caseating granuloma associated with lymphoid hyperplasia [4]. In their practice, of 2.5 years, the authors reported one case of granulomatous appendicitis, which is similar to the studies done by Ambekar S and Bhatia M and Pal S et al., [15,16].

CONCLUSION(S)

Granulomatous appendicitis is a rare disease and an incidental finding. It is an uncommon cause of acute abdomen and seen more commonly in young adult males. It is advisable to carry out careful sampling and serial sectioning of the appendix, once appendiceal granulomas are histologically recognised. Systemic and infectious causes of granulomatous inflammation of the appendix must be excluded with appropriate investigations prior to a diagnosis of idiopathic granulomatous appendicitis.

REFERENCES

- [1] Abdull Gaffar B. Granulomatous diseases and granulomas of the appendix. *Int J Surg Pathol.* 2010;18(1):14-20.
- [2] Colucci N, Meyer J, Puppa G, Toso C. Granulomatous appendicitis: A perioperative challenge. *BMJ Case Rep.* 2020;13(10):e238955.
- [3] Abedalqader T, Bakir M, AlJohani F, Altahan T, Amer SM, Almustanyir S. Acute abdomen secondary to granulomatous appendicitis: A rare case of complicated appendicitis. *Cureus.* 2022;14(3):e23247.
- [4] Rabhani K, Narjis Y, Difaa A, Louzi A, Benelkhaiat R, Finech B. Tuberculous appendicitis. *Saudi J Gastroenterol.* 2011;17(4):287-88.
- [5] Rasheed S, Zinicola R, Watson D, Bajwa A, McDonald PJ. Intra-abdominal and gastrointestinal tuberculosis. *Colorectal Dis.* 2007;9(9):773-83.
- [6] Sharath Chandra BJ, Girish TU, Thrishuli PB, Vinay HG. Primary tuberculosis of the appendix: A rare cause of a common disease. *J Surg Tech Case Rep.* 2013;5(1):32-34.
- [7] Scott JR. Tuberculosis of the appendix. *Ann Surg.* 1917;66(6):648-53.
- [8] Sathiyamoorthy R, Kalaivani M, Aggarwal P, Gupta SK. Prevalence of pulmonary tuberculosis in India: A systematic review and meta-analysis. *Lung India.* 2020;37(1):45-52.
- [9] Bobrow ML, Friedman S. Tuberculous appendicitis. *Am J Surg.* 1956;91(3):389-93.
- [10] Shah RC, Mehta KN, Jalunhwala JM. Tuberculosis of the appendix. *J Ind Med Assoc.* 1967;49:138-40.
- [11] Gupta AK, Gupta SC, Keswani NK, Singh PA, Tripathi AK, Krishna V. Pathology of tropical appendicitis. *J Clin Pathol.* 1989;42:1169-72.
- [12] Mittal VK, Khanna SK, Gupta NM, Aikat M. Isolated tuberculosis of appendix. *Am Surg.* 1975;41(3):172-74.
- [13] Najafzadeh-Sari S, Mehdizadeh H, Bagheri-Baghdasht MS, Manoochehy S. Suppurative appendicitis presenting acute scrotal pain: A rare condition may confuse surgeons. *J Surg Case Rep.* 2017;2017(10):rjx215.
- [14] Otsuka R, Shinoto K, Okazaki Y, Sato K, Hirano A, Isozaki T, et al. Crohn's disease presenting as granulomatous appendicitis. *Case Rep Gastroenterol.* 2019;13(3):398-402.

[15] Ambekar S, Bhatia M. Appendicular tuberculosis: A less encountered clinical entity. *BMJ Case Rep.* 2021;14(2):e237718.

[16] Pal S, Bose K, Chowdhury M, Sikder M. Tuberculous appendicitis: A rare case report. *Chrimed J Health Res.* 2016;3:144-46.

PARTICULARS OF CONTRIBUTORS:

1. Postgraduate Student, Department of Pathology, MS Ramaiah Medical College, Bengaluru, Karnataka, India.
2. Assistant Professor, Department of Pathology, MS Ramaiah Medical College, Bengaluru, Karnataka, India.

NAME, ADDRESS, E-MAIL ID OF THE CORRESPONDING AUTHOR:

Dr Usha Muniyappa,
Assistant Professor, Department of Pathology, MS Ramaiah Medical College,
Bengaluru-560054, Karnataka, India.
E-mail: usharavitha@gmail.com

PLAGIARISM CHECKING METHODS: [\[Jain H et al.\]](#)

- Plagiarism X-checker: Dec 13, 2022
- Manual Googling: Feb 21, 2023
- iThenticate Software: Mar 15, 2023 (18%)

ETYMOLOGY: Author Origin**EMENDATIONS:** 9**AUTHOR DECLARATION:**

- Financial or Other Competing Interests: None
- Was informed consent obtained from the subjects involved in the study? Yes
- For any images presented appropriate consent has been obtained from the subjects. Yes

Date of Submission: **Oct 02, 2022**Date of Peer Review: **Dec 14, 2022**Date of Acceptance: **Mar 16, 2023**Date of Publishing: **Jun 01, 2023**